



UNIVERSITY OF HELSINKI



<https://helda.helsinki.fi>

"\_"

---

## Rapid selection of BRCA1-proficient tumor cells during neoadjuvant therapy for ovarian cancer in BRCA1 mutation carriers

Sokolenko, Anna P.

ELSEVIER IRELAND LTD

2017-07-01

---

Sokolenko, A P, Savonevich, E L, Ivantsov, A O, Raskin, G A, Kuligina, E S, Gorodnova, T V, Preobrazhenskaya, E V, Kleshchov, M A, Tiurin, V I, Mukhina, M S, Kotiv, K B, Shulga, A V, Kuznetsov, S G, Berlev, I V & Imyanitov, E N 2017, 'Rapid selection of BRCA1-proficient tumor cells during neoadjuvant therapy for ovarian cancer in BRCA1 mutation carriers', *Cancer Letters*, vol. 397, pp. 127-132. <https://doi.org/10.1016/j.canlet.2017.03.036>

---

<http://hdl.handle.net/10138/235610>

[10.1016/j.canlet.2017.03.036](https://doi.org/10.1016/j.canlet.2017.03.036)

---

unspecified

publishedVersion


---

*Downloaded from Helda, University of Helsinki institutional repository.*

*This is an electronic reprint of the original article.*

*This reprint may differ from the original in pagination and typographic detail.*

*Please cite the original version.*



## Original Article

## Rapid selection of BRCA1-proficient tumor cells during neoadjuvant therapy for ovarian cancer in *BRCA1* mutation carriers



Anna P. Sokolenko<sup>a, b</sup>, Elena L. Savonevich<sup>c</sup>, Alexandr O. Ivantsov<sup>a</sup>, Grigory A. Raskin<sup>d</sup>, Ekatherina S. Kuligina<sup>a</sup>, Tatiana V. Gorodnova<sup>a</sup>, Elena V. Preobrazhenskaya<sup>a</sup>, Maxim A. Kleshchov<sup>a</sup>, Vladislav I. Tiurin<sup>a</sup>, Marina S. Mukhina<sup>d</sup>, Khristina B. Kotiv<sup>a</sup>, Andrey V. Shulga<sup>c</sup>, Sergey G. Kuznetsov<sup>e</sup>, Igor V. Berlev<sup>a</sup>, Evgeny N. Imyanitov<sup>a, b, f, g, \*</sup>

<sup>a</sup> Department of Tumor Biology, N.N. Petrov Institute of Oncology, St.-Petersburg 197758, Russia

<sup>b</sup> Department of Medical Genetics, St.-Petersburg Pediatric Medical University, St.-Petersburg 194100, Russia

<sup>c</sup> Department of Obstetrics and Gynecology, Grodno State Medical University, Grodno 230023, Belarus

<sup>d</sup> Department of Pathology, Russian Research Centre for Radiology and Surgical Technologies, St. Petersburg 197758, Russia

<sup>e</sup> Institute for Molecular Medicine Finland (FIMM), University of Helsinki, Helsinki 00290, Finland

<sup>f</sup> Department of Medical Genetics, I.I. Mechnikov North-Western Medical University, St.-Petersburg 191015, Russia

<sup>g</sup> Department of Oncology, St.-Petersburg State University, St.-Petersburg 199034, Russia

## ARTICLE INFO

## Article history:

Received 6 March 2017

Accepted 27 March 2017

## Keywords:

*BRCA1*

Ovarian cancer

Neoadjuvant therapy

Loss-of-heterozygosity

Treatment resistance

## ABSTRACT

Ovarian carcinomas (OC) often demonstrate rapid tumor shrinkage upon neoadjuvant chemotherapy (NACT). However, complete pathologic responses are very rare and the mechanisms underlying the emergence of residual tumor disease remain elusive. We hypothesized that the change of somatic *BRCA1* status may contribute to this process. The loss-of-heterozygosity (LOH) at the *BRCA1* locus was determined for 23 paired tumor samples obtained from *BRCA1* germ-line mutation carriers before and after NACT. We observed a somatic loss of the wild-type *BRCA1* allele in 74% (17/23) of OCs before NACT. However, a retention of the wild-type *BRCA1* copy resulting in a reversion of LOH status was detected in 65% (11/17) of those patients after NACT. Furthermore, we tested 3 of these reversion samples for LOH at intragenic *BRCA1* single nucleotide polymorphisms (SNPs) and confirmed a complete restoration of the SNP heterozygosity in all instances. The neoadjuvant chemotherapy for *BRCA1*-associated OC is accompanied by a rapid expansion of pre-existing *BRCA1*-proficient tumor clones suggesting that continuation of the same therapy after NACT and surgery may not be justified even in patients initially experiencing a rapid tumor regression.

© 2017 Elsevier B.V. All rights reserved.

## Introduction

*BRCA1* and *BRCA2* germ-line mutations account for approximately 15% of ovarian cancer (OC) morbidity [1,2]. Tumor development in *BRCA1/2* heterozygotes usually involves a somatic inactivation of the remaining *BRCA* allele, thus resulting in a compromised DNA repair via homologous recombination.

**Abbreviations:** HRM, high-resolution melting; IDS, interval debulking surgery; IHC, immunohistochemistry; LOH, loss-of-heterozygosity; NACT, neoadjuvant chemotherapy; OC, ovarian carcinoma; PDS, primary debulking surgery; SNP, single nucleotide polymorphisms.

\* Corresponding author. Department of Tumor Biology, N.N. Petrov Institute of Oncology, St.-Petersburg 197758, Russia. Fax: +7 812 5968947.

E-mail address: [evgeny@imyanitov.spb.ru](mailto:evgeny@imyanitov.spb.ru) (E.N. Imyanitov).

Accordingly, *BRCA1/2*-associated tumors demonstrate a high sensitivity to several DNA-damaging drugs and PARP inhibitors, and often have improved treatment outcomes as compared to sporadic neoplasms [3,4].

We recently performed a pilot study of the tumor material from *BRCA1*-heterozygous OC patients and obtained evidence for a rapid selection of *BRCA1*-proficient tumor clones during the neoadjuvant chemotherapy (NACT). While chemonaive carcinomas subjected to the primary debulking surgery (PDS) had expectedly a high rate (9 out of 11, 82%) of the loss-of-heterozygosity (LOH) at the *BRCA1* locus, tumors removed after NACT carried a deletion of the wild-type *BRCA1* allele only in 7/24 (29%) cases. Furthermore, a direct comparison of tumor pairs obtained before and after NACT confirmed the reversion of somatic *BRCA1* status in 2 out of 3 informative patients [2]. It is highly surprising that replacement of

the tumor mass with BRCA1-proficient cells occurs already at the very beginning of the systemic therapy course and takes such a short period of time. Furthermore, this observation may have some practical implications. When preoperative therapy leads to a significant reduction of the OC volume, it is a common practice to administer the same regimen after the surgery [5,6]. However, if a BRCA1-associated tumor restores BRCA1 function already during neoadjuvant treatment, it is doubtful whether continuation of the platinum therapy after the interval debulking surgery (IDS) is biologically justified.

In order to validate our initial findings, we significantly extended the number of BRCA1-related neoadjuvant OC cases, and undertook a systematic study of the BRCA1 status in pre- and post-treatment tumor pairs.

## Materials and methods

BRCA1 germ-line mutation carriers were identified via the analysis of Slavic founder alleles in BRCA1 gene [2,7]. Flow-chart describing the collection of hereditary OC cases is presented in the Supplementary Material (Fig. S1).

Primary chemo-naïve cancer cells were isolated from archival cytological slides (n = 21) or tumor biopsies (n = 2); post-NACT tumor samples were obtained from surgically removed material. The dissection of tumor cells and DNA extraction are described in Mitiushkina et al. [8]. BRCA1 LOH was assessed by real-time allele-specific PCR (AS-PCR) using mutation- and wild-type-specific primers [9,10]. Cases demonstrating the reversion of LOH status during neoadjuvant therapy were additionally analyzed by at least one independent method (Supplementary Table S2). QX100™ Droplet Digital PCR System (Bio-Rad, USA) was utilized for the validation of LOH results obtained for BRCA1 5382insC (c.5266dupC) mutation carriers (see primers and probes in the Supplementary Table S1); the threshold for LOH was a two-fold difference in the count of wild-type and mutant-specific signals. Those samples, which failed droplet PCR amplification, were subjected to conventional allele-specific PCR with fluorescently-labeled primers (Supplementary Table S2); the intensity of peaks corresponding to the total amount of mutation-specific and wild-type-specific PCR products was measured by Nanophore-5

genetic analyzer (Syntol, Russia), and the ratio (R) between these values was calculated for pre-NACT (R1) and post-NACT (R2) tumors. LOH reversion status was assigned to the pairs with R1/R2 score equal or greater than 2. LOH reversion in the OC pairs obtained from BRCA1 4153delA (c.4034delA) or C61G (c.181T > G) mutation carriers was validated by Sanger sequencing (Supplementary Table S2).

Search for single-nucleotide polymorphisms (SNPs) within BRCA1 gene was performed using high resolution melting analysis (HRM) and Sanger sequencing [11]. The analysis of TP53 mutations (exons 4–8) was carried out as described in Sokolenko et al. [12].

Immunohistochemical (IHC) staining was carried out using mouse monoclonal antibody for BRCA1 (clone MS110; dilution 1:100; Calbiochem, Merck Millipore, Germany), rabbit monoclonal antibody for Ki-67 (clone SP6; dilution 1:200; Spring Bioscience, Roche, Germany) and EnVision Flex HRP visualization system (DAKO, Carpinteria, CA). BRCA1/CEN17q probes (Abnova, Taiwan) and HER2 FISH pharmDx™ kit were used for FISH analysis.

## Results

We obtained paired tumor samples from 23 OC patients before and after NACT. First, we determined that 17/23 (74%) pre-treatment samples contained LOH at the BRCA1 locus. All instances of LOH involved a loss of the wild-type allele. Next, we analyzed the material surgically removed after NACT and revealed the retention of the wild-type BRCA1 copy in 11 (65%) of 17 tumors that have shown LOH before NACT (Table 1; Fig. 1). Among 11 tumors with the restored BRCA1 heterozygosity, 8 (73%) were exposed to 3 or more cycles of NACT, while 3 (27%) underwent surgery after 2 cycles of systemic treatment. Patients with preserved LOH during NACT tended to have shorter duration of pre-operative chemotherapy: 2 out of these 6 women received only 1 cycle of NACT (OCT57, OCT63) and 1 additional patient underwent surgery after 2 cycles of treatment (OCT49). An apparent gain of BRCA1 LOH after NACT was documented in 1 patient (OCT62, Table 1).

**Table 1**  
LOH status in BRCA1-associated ovarian carcinomas before and after neoadjuvant therapy.

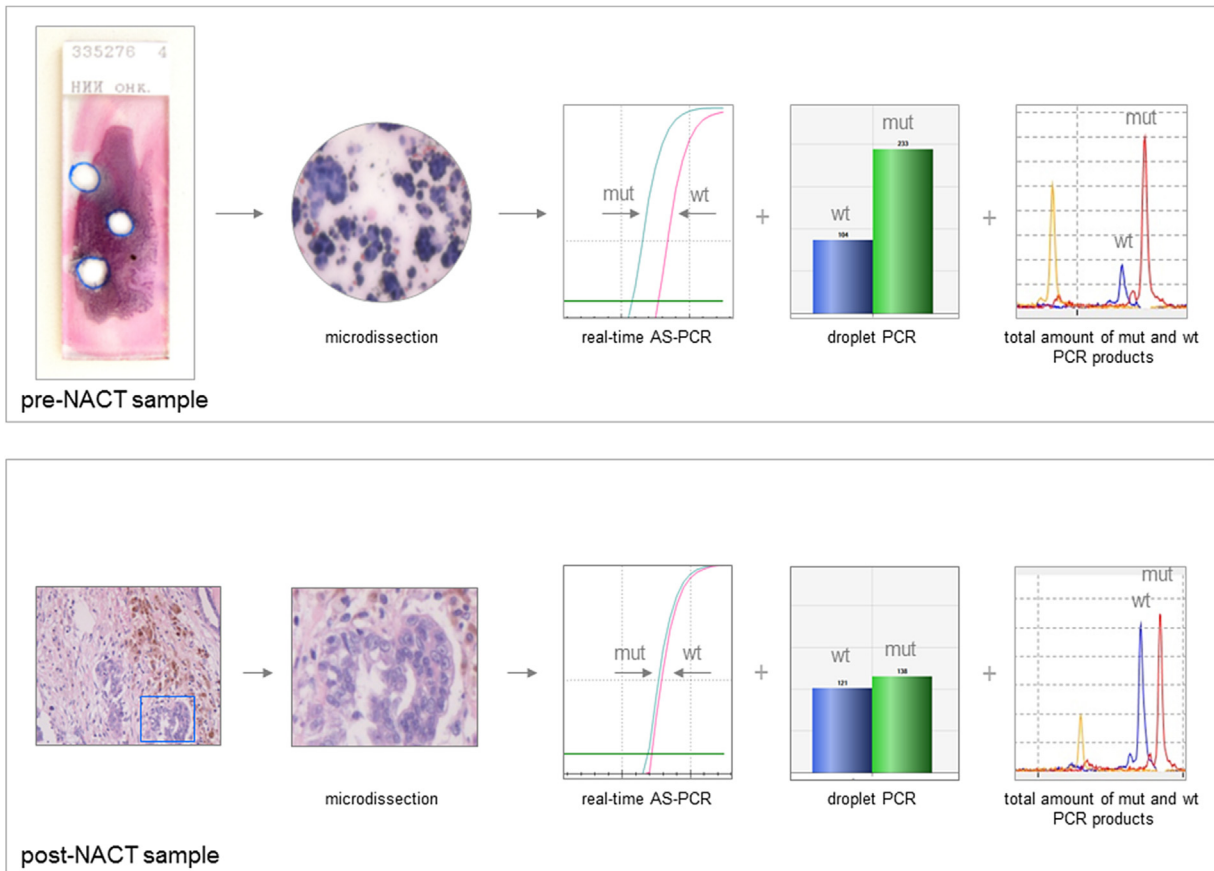
| ID    | BRCA1 germ-line mutation | TNM     | Histology             | Before NACT |               | Treatment (number of cycles) <sup>a</sup> | After NACT       |               | Histopathologic response <sup>b</sup> | Restoration of BRCA1 heterozygosity |
|-------|--------------------------|---------|-----------------------|-------------|---------------|---|------------------|---------------|---------------------------------------|-------------------------------------|
|       |                          |         |                       | LOH status  | TP53 mutation |   | LOH status       | TP53 mutation |                                       |                                     |
| OCT51 | 5382insC [c.5266dupC]    | T3cNxM0 | Serous adenocarcinoma | LOH         | WT            | CP (1), TP (1), CP (1), CCbP (1)          | No LOH           | p.E171D       | Good                                  | Yes                                 |
| OCT1  | 4153delA [c.4034delA]    | T3cNxM1 | Serous adenocarcinoma | LOH         | p.V272G       | TCbP (3)                                  | No LOH           | WT            | Good                                  | Yes                                 |
| OCT14 | 5382insC [c.5266dupC]    | T3cNxM0 | Serous adenocarcinoma | LOH         | p.E298X       | CP (3)                                    | No LOH           | p.E298X       | Good                                  | Yes                                 |
| OCT60 | 5382insC [c.5266dupC]    | T3cNxM0 | Serous adenocarcinoma | LOH         | p.R110P       | TP (6)                                    | No LOH           | p.R110P       | Good                                  | Yes                                 |
| OCT24 | 5382insC [c.5266dupC]    | T3cNxM1 | Serous adenocarcinoma | LOH         | p.R248Q       | CP (9)                                    | No LOH           | WT            | Moderate                              | Yes                                 |
| OCT58 | 5382insC [c.5266dupC]    | T3cNxM1 | Serous adenocarcinoma | LOH         | WT            | PMMC (3)                                  | No LOH           | WT            | Moderate                              | Yes                                 |
| OCT21 | 5382insC [c.5266dupC]    | T3cNxM0 | Serous adenocarcinoma | LOH         | p.M246V       | CP (3)                                    | No LOH           | WT            | Moderate                              | Yes                                 |
| OCT53 | 5382insC [c.5266dupC]    | T3cNxM0 | Serous adenocarcinoma | LOH         | WT            | EC (1), TCbP (1)                          | No LOH           | WT            | No                                    | Yes                                 |
| OCT5  | 4153delA [c.4034delA]    | T3cNxM1 | Serous adenocarcinoma | LOH         | c.148insA     | CP (2), P (6)                             | No LOH           | WT            | No                                    | Yes                                 |
| OCT52 | 5382insC [c.5266dupC]    | T3cNxM0 | Serous adenocarcinoma | LOH         | p.H179L       | CP (1), CCbP (1)                          | No LOH           | p.H179L       | No                                    | Yes                                 |
| OCT54 | C61G [c.181T > G]        | T3cNxM0 | Serous adenocarcinoma | LOH         | WT            | CP (1), CCbP (1)                          | No LOH           | WT            | No                                    | Yes                                 |
| OCT50 | 5382insC [c.5266dupC]    | T3cNxM1 | Serous adenocarcinoma | LOH         | p.R248Q       | TCbP (4)                                  | LOH              | p.R248Q       | Moderate                              | No                                  |
| OCT56 | 4153delA [c.4034delA]    | T3cNxM0 | Serous adenocarcinoma | LOH         | WT            | CP (3)                                    | LOH              | WT            | No                                    | No                                  |
| OCT49 | 5382insC [c.5266dupC]    | T3cNxM0 | Serous adenocarcinoma | LOH         | p.R248Q       | TP (1), CP (1)                            | LOH              | p.R248Q       | No                                    | No                                  |
| OCT57 | C61G [c.181T > G]        | T3cNxM0 | Serous adenocarcinoma | LOH         | WT            | CCbP (1)                                  | LOH              | c.898delC     | No                                    | No                                  |
| OCT63 | 5382insC [c.5266dupC]    | T3cNxM0 | Serous adenocarcinoma | LOH         | p.G245S       | TP (1)                                    | LOH              | p.G245S       | No                                    | No                                  |
| OCT16 | 5382insC [c.5266dupC]    | T3cNxM0 | Serous adenocarcinoma | LOH         | ND            | CAP (1), topotecan (2)                    | LOH <sup>c</sup> | WT            | Not applicable <sup>c</sup>           | No                                  |
| OCT9  | 4153delA [c.4034delA]    | T3cNxM0 | Serous adenocarcinoma | No LOH      | WT            | CP (2)                                    | No LOH           | WT            | Good                                  | NI                                  |
| OCT29 | 5382insC [c.5266dupC]    | T3cNxM1 | Serous adenocarcinoma | No LOH      | c.757insA     | CP (2)                                    | No LOH           | WT            | Good                                  | NI                                  |
| OCT62 | 5382insC [c.5266dupC]    | T3cNxM0 | Serous adenocarcinoma | No LOH      | WT            | CCbP (2)                                  | LOH              | p.R196X       | Good                                  | NI                                  |
| OCT61 | 4153delA [c.4034delA]    | T3cNxM0 | Serous adenocarcinoma | No LOH      | WT            | CP (3), CCbP (1)                          | No LOH           | WT            | Good                                  | NI                                  |
| OCT55 | 4153delA [c.4034delA]    | T3cNxM0 | Serous adenocarcinoma | No LOH      | WT            | CP (3)                                    | No LOH           | WT            | No                                    | NI                                  |
| OCT59 | 5382insC [c.5266dupC]    | T3cNxM0 | Serous adenocarcinoma | No LOH      | WT            | TP (1), TCbP (4)                          | No LOH           | WT            | No                                    | NI                                  |

ND – no data, NI – non-informative (no LOH in cytological sample).

<sup>a</sup> CP – cyclophosphamide 1000 mg/m<sup>2</sup> + cisplatin 50 mg/m<sup>2</sup>; CAP – cyclophosphamide 500 mg/m<sup>2</sup> + doxorubicin 60 mg/m<sup>2</sup> + cisplatin 50 mg/m<sup>2</sup>; TCbP – paclitaxel 175 mg/m<sup>2</sup> + carboplatin (6 AUC); P – cisplatin monotherapy 100 mg/m<sup>2</sup>; CCbP – cyclophosphamide 600 mg/m<sup>2</sup> + carboplatin 300 mg/m<sup>2</sup>, TP – paclitaxel 175 mg/m<sup>2</sup> + cisplatin 75 mg/m<sup>2</sup>, PMMC – cisplatin 100 mg/m<sup>2</sup> + mitomycin C 10 mg/m<sup>2</sup>, EC – epirubicin 60 mg/m<sup>2</sup> + cyclophosphamide 200 mg/m<sup>2</sup>, topotecan – topotecan 1.5 mg/m<sup>2</sup>/day for 5 days.

<sup>b</sup> According to Sassen S et al. [33].

<sup>c</sup> Only metastatic lesions was available for analysis.



**Fig. 1.** *BRCA1* LOH status determination in pre-NACT and post-NACT tumor tissues. Chemo-naive sample from patient OCT60 (Table 1) demonstrates somatic loss of the wild-type *BRCA1* allele (top); in contrast, cancer cells excised after platinum-based therapy show the retention of the normal *BRCA1* gene copy (bottom). Equivalent results are obtained by allele-specific real-time PCR, digital droplet PCR and direct quantitation of the total amount of allele-specific PCR products.

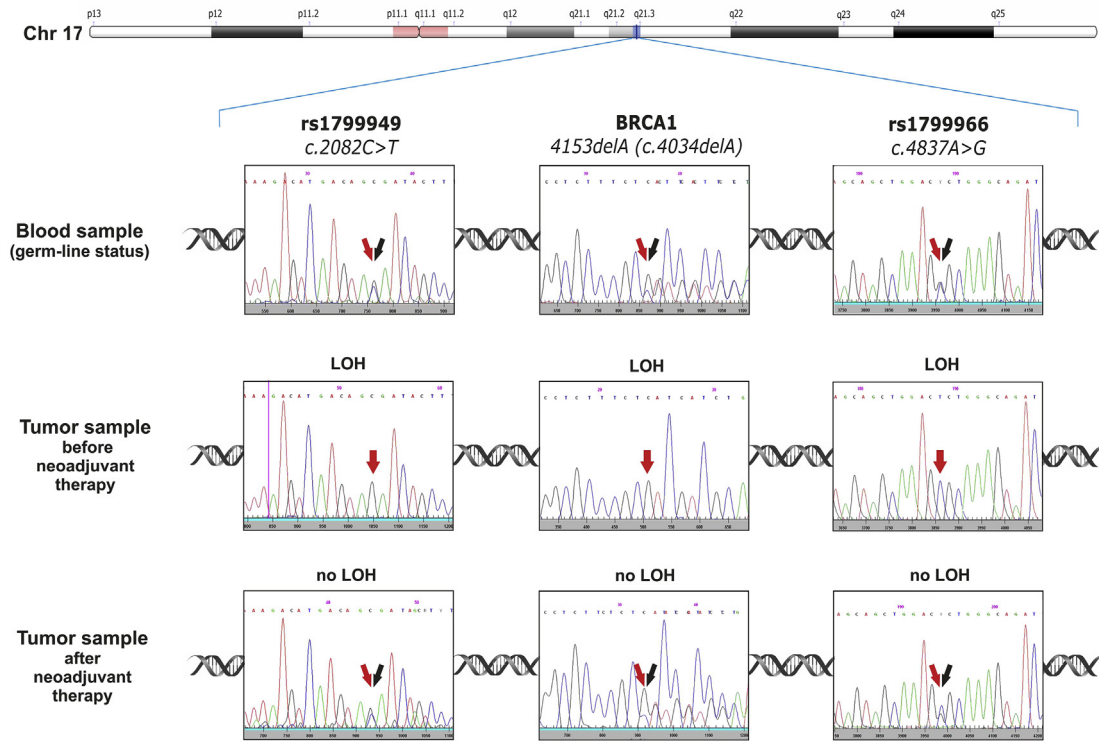
We further questioned, whether the restoration of the *BRCA1* function in post-treatment tumor samples was related to a back mutation of the mutant *BRCA1* allele or to the expansion of pre-existing *BRCA1*-proficient tumor clones. To resolve this issue, we screened normal DNA samples for linked single nucleotide polymorphisms (SNPs) within the *BRCA1* gene. A high-molecular weight blood DNA was available for 5 out of 11 samples with the reversion of the LOH status. Using Sanger sequencing, we detected SNPs in three of these patients (OCT1 [rs1799949; rs1799966]; OCT5 [rs799923]; OCT21 [rs1799949; rs1799966]). Similar to deleterious *BRCA1* mutations, these SNPs revealed LOH in the chemo-naive samples, but retained heterozygosity in the surgically removed tumors (Fig. 2 and data not shown). Therefore, the restoration of *BRCA1* heterozygosity in OC tissue after NACT occurs not due to a back mutation, but can be explained by a rapid selection of pre-existing *BRCA1*-proficient clones under the selective pressure of platinum compounds.

We also analyzed paired tissue samples from the OCT14 patient (Table 1) using IHC and FISH (Fig. 3). Neoadjuvant therapy was accompanied by a dramatic decline of the Ki-67 index. This patient's chemo-naive tumor tissue was largely negative for *BRCA1* IHC expression, although few *BRCA1*-positive single cells were visible. This is consistent with the data on a decreased stability of the protein encoded by the *BRCA1* 5382insC allele [13]. A selection of *BRCA1*-heterozygous cells after NACT was accompanied by an evident increase in the *BRCA1* IHC reactivity. Furthermore, a *BRCA1* FISH analysis of the pre-NACT tumor tissue revealed a loss of one copy each for *BRCA1* (red signal) and the chromosome 17 centromeric (green signal) probes, suggesting that *BRCA1* LOH is

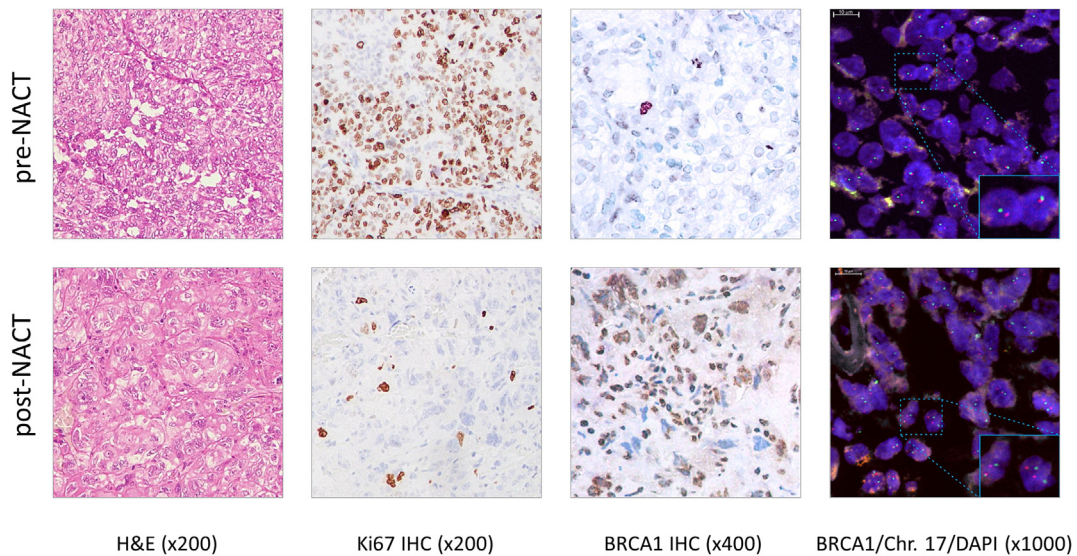
associated with a deletion of a large region of the chromosome 17. In agreement with the reversion of the *BRCA1* LOH status, the post-NACT tumor was biallelic for both these probes (Fig. 3). This result was further supported by the FISH analysis of the *HER2* gene, which lies in the vicinity of the *BRCA1* locus (17q12 and 17q21, correspondingly; data not shown).

*BRCA1* deficiency is poorly compatible with cell viability, thus tumors arising in *BRCA1* germ-line mutation carriers often acquire *TP53* mutations in order to escape apoptosis [14,15]. Given that this study involved a partially degraded DNA obtained from small archival biological specimens, the *TP53* DNA sequencing analysis was confined only to exons 4–8. Bearing this in mind, we identified pathogenic *TP53* mutations in 11/22 (50%) pre-NACT samples, including 10/16 (63%) informative tumors with *BRCA1* LOH and 1/6 (17%) without *BRCA1* LOH ( $p = 0.07$ ). In post-NACT tumors, 9 out of 23 (39%) cases were positive for *TP53* mutations, including 5/7 cases (71%) with *BRCA1* LOH and 4/16 (25%) cases without LOH ( $p = 0.05$ ) suggesting a trend to association between a mutant *TP53* status and a loss of the wild-type *BRCA1* allele (Table 1).

For those 11 cases where *BRCA1* LOH status was restored after NACT, the *TP53* mutation status did not change in 6 cases (55%), while in 4 cases (36%) a mutant *TP53* detected before NACT changed to wild-type thereafter, and in 1 case (9%) initially wild-type *TP53* became mutant after NACT (Table 1, Fig. 4). For the 5 informative cases where an initially detected *BRCA1* LOH did not change after NACT, the *TP53* mutation status did not change in 4 (80%) cases (3 mutants and 1 wild-type), while in 1 case initially wild-type *TP53* became mutated. There were no cases where a mutant *TP53* would become a wild-type if *BRCA1* LOH status did not change. For the 6



**Fig. 2.** LOH analysis of *BRCA1* gene SNPs. Chemo-naive tumor from patient OCT5 shows somatic LOH both the wild-type *BRCA1* allele and for the linked SNPs. All three *BRCA1* markers (4153delA; rs1799949; rs1799966) demonstrate restoration of heterozygosity in the post-NACT samples. Similar results were obtained for two remaining tumors with informative SNPs (OCT1 and OCT21; data not shown). Taken together, these observations provide strong evidence that restoration of intratumoral *BRCA1* function occurs via selection of preexisting *BRCA1*-proficient tumor clones, but not due to back mutation.

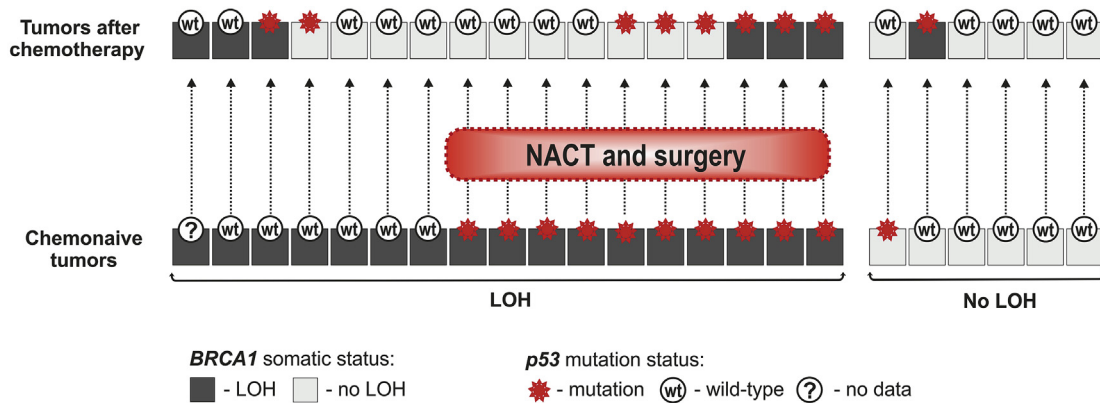


**Fig. 3.** IHC and FISH analysis of pre- and post-NACT ovarian cancer samples. Neoadjuvant chemotherapy results in expansion of *BRCA1*-proficient cells, as evidenced both by IHC analysis of *BRCA1* expression and the selection of *BRCA1* biallelic cells determined by FISH. See also comments in the text.

cases that didn't show *BRCA1* LOH before the treatment, the *TP53* mutation status (WT) did not change after the treatment in 4 cases (67%). In all these 4 cases the *BRCA1* LOH status did not change either. Nevertheless, in 2 other cases the *TP53* mutation status was different before and after treatment. In one case (OCT29), a mutant *TP53* in the pre-NACT tumor became WT in the post-NACT tumor. Both samples from this case revealed no LOH for *BRCA1*. In the second case (OCT62), an initially WT *TP53* acquired a pathogenic

mutation after the treatment. Interestingly, this was the only instance, in which we failed to detect *BRCA1* LOH in the chemo-naive tumor, while observing a deletion of the wild-type *BRCA1* in the post-NACT neoplastic tissue.

A histopathologic tumor response was observed in 7 out of 11 (64%) tumors with the reversion of *BRCA1* LOH status, including 4 good and 3 moderate responders. In contrast, only 1 (20%) out of 5 informative cases with preserved LOH before and after NACT



**Fig. 4.** *BRCA1* LOH and *TP53* status in pre- and post-NACT ovarian carcinomas. *TP53* mutations tend to occur more often in tumors with the somatic deletion of the wild-type *BRCA1* allele. Change of *BRCA1* LOH status during NACT is accompanied by the change of *TP53* mutation status in some but not all tumor pairs.

showed a moderate histopathologic response ( $p = 0.14$ ). Among 6 tumors with the retention of *BRCA1* heterozygosity in the chemo-naive tumor tissue, 4 patients (67%) demonstrated a good histopathologic response (Table 1).

## Discussion

The utility of the neoadjuvant therapy for the treatment of ovarian cancer is a subject of intense debates [16–21]. The preoperative use of platinum agents usually results in significant reduction of tumor volume, thus allowing for a less traumatic surgery and a low perioperative morbidity. However, opponents of NACT insist that anticancer drugs cannot efficiently penetrate large tumor masses, thus causing many OC cells to escape drug uptake before the surgery. Furthermore, NACT may convert OC lumps into macroscopically invisible lesions, which can be missed during a surgical inspection. In addition, the presence of a high tumor burden at the beginning of the therapy increases the chances of efficient selection of resistant tumor clones during the preoperative exposure to platinum agents. A direct comparison of OC treatment schemes involving NACT followed by interval debulking surgery and postoperative systemic therapy versus PDS followed by adjuvant therapy is critically compromised by a huge variability of surgical attitudes between different hospitals. It is acknowledged that even if a tumor rapidly shrinks upon the neoadjuvant treatment and all visible malignant lumps are successfully removed during IDS, the presence of residual cancer cells in surgically removed tissues is associated with a high risk of relapse despite the continuation of an apparently effective systemic therapy [21]. The current study provides a mechanistic explanation to this phenomenon, at least for cancers arising in *BRCA1* mutation carriers: in contrast to primary LOH-bearing OC samples, the systemically treated tumor tissues often retain a normal copy of *BRCA1* gene by the time of surgery and, therefore, are likely to be non-responsive to the continuing platinum-based therapy.

The emergence of tumor resistance during a systemic therapy is well known, however, this process was believed to take at least several months [22]. Here we demonstrate that depletion of *BRCA1*-deficient tumor cells in OCs may occur within a few weeks of the neoadjuvant treatment, and during this time tumors become rapidly repopulated by the *BRCA1*-proficient tumor clones. Given that *BRCA1*-proficient cells are hardly detectable in LOH-carrying tumors at the start of the therapy, it seems likely that the death of platinum-sensitive cells is accompanied by a very rapid proliferation of platinum-resistant clones to form a visible tumor mass within such a short period of time. Interestingly, recent studies

demonstrate an active interaction between drug-sensitive and -resistant clones during therapy: dying cancer cells can secrete molecules triggering proliferation and expansion of the subtle fraction of treatment-refractory cells [23].

Restoration of *BRCA1/2* function upon emerging resistance to platinum drugs or PARP inhibitors has been already demonstrated by several investigators [24–32]. Our study has essential differences as compared to the previous reports. First, the above studies involved mainly heavily pretreated patients, while we analyzed tumors exposed to a limited number of therapeutic cycles. Second, restoration of the *BRCA1* function during palliative treatment of metastatic OCs often involves additional genetic events directly in the germ-line mutation-bearing allele restoring the open reading frame of *BRCA1*. Some secondary mutations are located in the vicinity of the primary one, thus, resulting in a functional *BRCA1* protein, yet carrying small differences from the WT at the nucleotide sequence level. Other platinum-resistant tumors are characterized by a complete restoration of the wild-type *BRCA1* sequence caused by a back mutation. Here we provide a convincing evidence that the presence of the wild-type *BRCA1* in tumor masses removed after a neoadjuvant therapy can be explained by selection of pre-existing *BRCA1*-proficient cells rather than by a back mutation (Fig. 2). This conclusion is in agreement with the study of Martins et al. [15] showing that a somatic deletion of the *BRCA1* wild-type allele is not necessarily the very first event in the *BRCA1*-driven tumorigenesis, and that tumors arising in *BRCA1* mutation-carriers often contain a fraction of malignant cells with a retained *BRCA1* function. Furthermore, data on the heterogeneity of *BRCA1* LOH and *TP53* mutations confirm observations of Martins et al. [15] that no obligatory temporal order for these molecular events exists during tumor development (Table 1, Fig. 4).

Several limitations of the study have to be acknowledged, though. First, the determination of the LOH status did not account for the possible intratumoral heterogeneity. For example, an apparent gain of LOH during NACT in the case OCT62 could be explained not by the true absence of LOH in the chemo-naive tumor, but by the existence of genetically distinct tumor clones in the beginning of the therapy. Second, manipulations with tiny tumor masses, such as cytological slides or post-NACT samples, are technically challenging. Nevertheless, a significant impact of technical difficulties on our results seems unlikely. For example, several OC samples with *BRCA1* heterozygosity restored upon NACT still carried *TP53* mutations, which wouldn't be possible if tumor cells were dissected incorrectly. Third, although all therapeutic schemes were platinum-based, there were significant interpatient variations concerning the composition of cytotoxic cocktails and the number

of therapy cycles. For example, two patients included in this study received only one cycle of chemotherapy and demonstrated a preserved LOH status after NACT. It is questionable whether the data obtained for these women should be considered.

It remains to be further investigated, to what extent the reversion of the LOH status in BRCA1-mutated tumors after chemotherapy may influence their sensitivity to a subsequent treatment. In theory, a somatic inactivation of the wild-type BRCA1 allele should correlate with the sensitivity to a platinum-based therapy, while restoration of the BRCA1 heterozygosity after NACT may call for alternative treatment options. In this respect, our study may be practice-changing and lead to a re-evaluation of post-NACT treatment options for hereditary BRCA1 mutation-positive OC patients. Our results call for a separate clinical trial, in which the BRCA1 LOH status would be evaluated before and after NACT, on the one hand, and the efficiency of the same chemotherapeutic agents as before the surgery would be compared with alternative agents, to which the patients has not been exposed previously, on the other hand.

### Acknowledgments

Patient selection and clinical analysis is supported by the Russian Scientific Fund [grant number 14-25-00111]. Tissue analysis is supported by the Russian and Belorussian Foundations for Basic Research [grant number 16-54-00055/M16P-214].

### Appendix A. Supplementary data

Supplementary data related to this article can be found at <http://dx.doi.org/10.1016/j.canlet.2017.03.036>.

### Conflict of interest

There are no conflicts of interest in the studies reported in the paper.

### References

- [1] K. Alsop, S. Fereday, C. Meldrum, A. deFazio, C. Emmanuel, J. George, et al., BRCA mutation frequency and patterns of treatment response in BRCA mutation-positive women with ovarian cancer: a report from the Australian Ovarian Cancer Study Group, *J. Clin. Oncol.* 30 (2012) 2654–2663.
- [2] T.V. Gorodnova, A.P. Sokolenko, A.O. Ivantsov, A.G. Iyevleva, E.N. Suspitsin, S.N. Aleksakhina, et al., High response rates to neoadjuvant platinum-based therapy in ovarian cancer patients carrying germ-line BRCA mutation, *Cancer Lett.* 369 (2015) 363–367.
- [3] A.G. Iyevleva, E.N. Imyanitov, Cytotoxic and targeted therapy for hereditary cancers, *Heredit. Cancer Clin. Pract.* 14 (2016) 17.
- [4] C.J. Lord, A. Ashworth, BRCAness revisited, *Nat. Rev. Cancer* 16 (2016) 110–120.
- [5] I. Vergote, C.G. Tropé, F. Amant, G.B. Kristensen, T. Ehlen, N. Johnson, et al., Neoadjuvant chemotherapy or primary surgery in stage IIIc or IV ovarian cancer, *N. Engl. J. Med.* 363 (2010) 943–953.
- [6] S. Kehoe, J. Hook, M. Nankivell, G.C. Jayson, H. Kitchener, T. Lopes, et al., Primary chemotherapy versus primary surgery for newly diagnosed advanced ovarian cancer (CHORUS): an open-label, randomised, controlled, non-inferiority trial, *Lancet* 386 (2015) 249–257.
- [7] A. Savanevich, O. Oszurek, J. Lubiński, C. Cybulski, T. Dębniak, S.A. Narod, et al., BRCA1 founder mutations compared to ovarian cancer in Belarus, *Fam. Cancer* 13 (2014) 445–447.
- [8] N.V. Mitiushkina, A.G. Iyevleva, A.N. Poltoratskiy, A.O. Ivantsov, A.V. Togo, I.S. Polyakov, et al., Detection of EGFR mutations and EML4-ALK rearrangements in lung adenocarcinomas using archived cytological slides, *Cancer Cytopathol.* 121 (2013) 370–376.
- [9] A.P. Sokolenko, M.E. Rozanov, N.V. Mitiushkina, N.Y. Sherina, A.G. Iyevleva, E.V. Chekmariova, et al., Founder mutations in early-onset, familial and bilateral breast cancer patients from Russia, *Fam. Cancer* 6 (2007) 281–286.
- [10] E.N. Suspitsin, A.P. Sokolenko, D.A. Voskresenskiy, A.O. Ivantsov, K.V. Shelekhova, V.F. Klimashevskiy, et al., Mixed epithelial/mesenchymal metaplastic carcinoma (carcinosarcoma) of the breast in BRCA1 carrier, *Breast Cancer* 18 (2011) 137–140.
- [11] A.G. Iyevleva, E.N. Suspitsin, K. Kroeze, T.V. Gorodnova, A.P. Sokolenko, K.G. Buslov, et al., Non-founder BRCA1 mutations in Russian breast cancer patients, *Cancer Lett.* 298 (2010) 258–263.
- [12] A.P. Sokolenko, E.V. Preobrazhenskaya, S.N. Aleksakhina, A.G. Iyevleva, N.V. Mitiushkina, O.A. Zaitseva, et al., Candidate gene analysis of BRCA1/2 mutation-negative high-risk Russian breastcancer patients, *Cancer Lett.* 359 (2015) 259–261.
- [13] A.C. Nelson, J.T. Holt, Impact of RING and BRCT domain mutations on BRCA1 protein stability, localization and recruitment to DNA damage, *Radiat. Res.* 174 (2010) 1–13.
- [14] H. Holstege, S.A. Joosse, C.T. van Oostrom, P.M. Nederlof, A. de Vries, J. Jonkers, High incidence of protein-truncating TP53 mutations in BRCA1-related breast cancer, *Cancer Res.* 69 (2009) 3625–3633.
- [15] F.C. Martins, S. De, V. Almendro, M. Gönen, S.Y. Park, J.L. Blum, et al., Evolutionary pathways in BRCA1-associated breast tumors, *Cancer Discov.* 2 (2012) 503–511.
- [16] I. Vergote, F. Amant, K. Leunen, Neoadjuvant chemotherapy in advanced ovarian cancer: what kind of evidence is needed to convince US gynaecological oncologists? *Gynecol. Oncol.* 119 (2010) 1–2.
- [17] D.S. Chi, R.E. Bristow, D.K. Armstrong, B.Y. Karlan, Is the easier way ever the better way? *J. Clin. Oncol.* 29 (2011) 4073–4075.
- [18] C. Marth, A. Zeimet, A. Du Bois, Is neoadjuvant chemotherapy in ovarian cancer an excuse for insufficient surgery? *Oncology (Williston Park)* 25 (2011), 940, 942, 944.
- [19] I. Vergote, K. Leunen, F. Amant, Primary surgery or neoadjuvant chemotherapy in ovarian cancer: what is the value of comparing apples with oranges? *Gynecol. Oncol.* 124 (2012) 1–2.
- [20] J.O. Schorge, R.M. Clark, S.I. Lee, R.T. Penson, Primary debulking surgery for advanced ovarian cancer: are you a believer or a dissenter? *Gynecol. Oncol.* 135 (2014) 595–605.
- [21] A. Leary, R. Cowan, D. Chi, S. Kehoe, M. Nankivell, Primary surgery or neoadjuvant chemotherapy in advanced ovarian cancer: the debate continues..., *Am. Soc. Clin. Oncol. Educ. Book* 35 (2016) 153–162.
- [22] V. Giannakeas, V. Sopik, S.A. Narod, A model for ovarian cancer progression based on inherent resistance, *Gynecol. Oncol.* 142 (2016) 484–489.
- [23] A.C. Obenaus, Y. Zou, A.L. Ji, S. Vanharanta, W. Shu, H. Shi, et al., Therapy-induced tumour secretomes promote resistance and tumour progression, *Nature* 520 (2015) 368–372.
- [24] S.L. Edwards, R. Brough, C.J. Lord, R. Natrajan, R. Vatcheva, D.A. Levine, et al., Resistance to therapy caused by intragenic deletion in BRCA2, *Nature* 451 (2008) 1111–1115.
- [25] W. Sakai, E.M. Swisher, B.Y. Karlan, M.K. Agarwal, J. Higgins, C. Friedman, et al., Secondary mutations as a mechanism of cisplatin resistance in BRCA2-mutated cancers, *Nature* 451 (2008) 1116–1120.
- [26] W. Sakai, E.M. Swisher, C. Jacquemont, K.V. Chandramohan, F.J. Couch, S.P. Langdon, et al., Functional restoration of BRCA2 protein by secondary BRCA2 mutations in BRCA2-mutated ovarian carcinoma, *Cancer Res.* 69 (2009) 6381–6386.
- [27] E.M. Swisher, W. Sakai, B.Y. Karlan, K. Wurz, N. Urban, T. Taniguchi, Secondary BRCA1 mutations in BRCA1-mutated ovarian carcinomas with platinum resistance, *Cancer Res.* 68 (2008) 2581–2586.
- [28] K.K. Dhillon, E.M. Swisher, T. Taniguchi, Secondary mutations of BRCA1/2 and drug resistance, *Cancer Sci.* 102 (2011) 663–669.
- [29] B. Norquist, K.A. Wurz, C.C. Pennil, R. Garcia, J. Gross, W. Sakai, et al., Secondary somatic mutations restoring BRCA1/2 predict chemotherapy resistance in hereditary ovarian carcinomas, *J. Clin. Oncol.* 29 (2011) 3008–3015.
- [30] L.J. Barber, S. Sandhu, L. Chen, J. Campbell, I. Kozarewa, K. Fenwick, et al., Secondary mutations in BRCA2 associated with clinical resistance to a PARP inhibitor, *J. Pathol.* 229 (2013) 422–429.
- [31] C.J. Lord, A. Ashworth, Mechanisms of resistance to therapies targeting BRCA-mutant cancers, *Nat. Med.* 19 (2013) 1381–1388.
- [32] A.M. Patch, E.L. Christie, D. Etemadmoghadam, D.W. Garsed, J. George, S. Fereday, et al., Whole-genome characterization of chemoresistant ovarian cancer, *Nature* 521 (2015) 489–494.
- [33] S. Sassen, B. Schmalfeldt, N. Avril, W. Kuhn, R. Busch, H. Höfler, et al., Histopathologic assessment of tumor regression after neoadjuvant chemotherapy in advanced-stage ovarian cancer, *Hum. Pathol.* 38 (2007) 926–934.